

# Comparison of a Fractional Microplasma Radio Frequency Technology and Carbon Dioxide Fractional Laser for the Treatment of Atrophic Acne Scars: A Randomized Split-Face Clinical Study

ZHEN ZHANG, MD,<sup>\*†</sup> YE FEI, MD,<sup>\*†</sup> XIANGDONG CHEN, MD,<sup>\*†</sup> WENLI LU, MD,<sup>\*</sup> AND JINAN CHEN, MD<sup>†</sup>

---

**BACKGROUND** No studies have compared fractional microplasma radio frequency (RF) technology with the carbon dioxide fractional laser system (CO<sub>2</sub> FS) in the treatment of atrophic acne scars in the same patient.

**OBJECTIVE** To compare the efficacy and safety of fractional microplasma RF with CO<sub>2</sub> FS in the treatment of atrophic acne scars.

**METHODS AND MATERIALS** Thirty-three Asian patients received three sessions of a randomized split-face treatment of fractional microplasma RF or CO<sub>2</sub> FS.

**RESULTS** Both modalities had a roughly equivalent effect. Échelle d'Évaluation Clinique Des Cicatrices d'Acné scores were significantly lower after fractional microplasma RF (from 51.1 ± 14.2 to 22.3 ± 8.6, 56.4% improvement) and CO<sub>2</sub> FS (from 48.8 ± 15.1 to 19.9 ± 7.9, 59.2% improvement) treatments. There was no statistically significant difference between the two therapies. Twelve subjects (36.4%) experienced post-inflammatory hyperpigmentation (PIH) after 30 of 99 treatment sessions (30.3%) on the CO<sub>2</sub> FS side and no PIH was observed on the fractional microplasma RF sides.

**CONCLUSION** Both modalities have good effects on treating atrophic scars. PIH was not seen with the fractional microplasma RF, which might make it a better choice for patients with darker skin.

*The authors have indicated no significant interest with commercial supporters.*

---

Atrophic facial acne scarring is a widely prevalent condition that can have a negative effect on a patient's quality of life. There has been much research into the treatment of acne scars in an attempt to minimize them. Ablative lasers such as the carbon dioxide (CO<sub>2</sub>) laser have been considered to be the criterion standard for skin resurfacing, but the procedures are associated with long healing times, edema, prolonged erythema, post-therapy dyschromias, and scarring.<sup>1,2</sup> Ablative fractional resurfacing using the CO<sub>2</sub> fractional laser system

(FS) has demonstrated significant beneficial effects on atrophic acne scars and minor side effects,<sup>3,4</sup> but for Asians with Fitzpatrick skin type III or, the cause of the post-therapy hyperpigmentation cannot be ignored.<sup>5-7</sup>

More recently, a fractional microplasma radio-frequency (RF) device has been developed that allows treatment of the face with fractional RF based on the rationale of placing a grid of high-energy foci on the skin.<sup>8,9</sup> The electromagnetic RF

<sup>\*</sup>Department of Dermatology, Shanghai Ninth People's Hospital, School of Medicine, Shanghai JiaoTong University; <sup>†</sup>Laser Cosmetic Centre, Shanghai Ninth People's Hospital, School of Medicine, Shanghai JiaoTong University, Shanghai, China

energy may achieve an ablative effect along with the thermal effect. The technology was overall safe and effective in the treatment of acne scars. The objective of this prospective study was to determine whether fractional microplasma RF could provide better efficacy and patient satisfaction and fewer adverse effects than CO<sub>2</sub> FS in the treatment of atrophic facial acne scars in Asians.

## Materials and Methods

We conducted an evaluator-blinded, randomized, comparative split-face study of fractional microplasma RF and CO<sub>2</sub> FS treatments for atrophic acne scars. This study was performed in accordance with the ethical guidelines of the 1975 Declaration of Helsinki and approved by Shanghai Ninth People's Hospital, Shanghai Jiao Tong University School of Medicine, Shanghai, China.

## Patients

Patients with atrophic acne scars on both sides of the face were recruited for the study. Informed consent was obtained from all patients. Exclusion criteria were pregnancy; breastfeeding; history of keloid tendency; immunosuppression; photosensitivity or current use of photosensitive medication; oral isotretinoin use in the preceding 6 months; use of topical retinoids in the preceding 2 weeks; active dermatitis; infection or malignancy over the treatment area; and having received light source, RF, or laser skin resurfacing treatments in the 6 months before the study.

## Laser Treatment

Facial halves were randomly assigned to receive treatment with a CO<sub>2</sub> FS (10,600-nm Ultrapulse Encore; Lumenis Inc., Santa Clara, CA) on one side and fractional microplasma RF (Accent; Alma Lasers, Caesarea, Israel) on the contralateral side. For local anesthesia, after the face was cleansed with a mild soap and 70% alcohol, a topical eutectic mixture of 2.5% lidocaine hydrochloric acid and 2.5% prilocaine (Beijing Ziguang Medication

Manufacture Corporation Ltd, Beijing, China) was applied to the entire face under occlusion 1 hour before the therapy. Patients with a history of herpes virus infection were prescribed oral valacyclovir hydrochloride 500 mg twice a day for 7 days commencing 2 days before each treatment.

The parameters for the CO<sub>2</sub> FS treatment were 20 to 25 mJ, density 2 to 4 (10–20% coverage/cm<sup>2</sup> per pass), 300 Hz, using the Deep FX mode, and one pass without overlapping. During fractional microplasma RF treatment, the face was treated with four passes of the roller tip at 50 to 60 W. All patients received three treatment sessions at intervals of 6 to 12 (average 8) weeks. For subjects who experienced postinflammatory hyperpigmentation (PIH), the next treatment session occurred after the dyspigmentation had been completely resolved. Two board-certified dermatologists who did not participate in outcome assessments performed treatments.

Postoperatively, all patients were instructed to cleanse the treated sites gently with tap water and use a moisturizer (Cicaplast; La Roche-Posay, Paris, France) twice a day. Sun avoidance and the use of a sunscreen with a sun protection of 50 (Anthelios XL; La Roche-Posay, Paris, France) was encouraged.

## Objective and Subjective Evaluations

All patients were photographed four times (before each treatment session and 6 months after the last session) in the same position, with the same lighting and camera setup and by the same photographer, using a digital camera (Nikon D90, Tokyo, Japan). Two unbiased, board-certified dermatologists conducted blinded clinical assessments of the treatment areas using comparative photographs. Acne scar improvements were quantified according to Échelle d'Évaluation Clinique Des Cicatrices d'Acné (ECCA; Clinical Evaluation Scale for Acne Scarring) scores.<sup>10</sup> To elucidate relationships between acne scar subtypes and response to laser treatments, we classified acne scars into five subtypes according to

shape and depth (superficial or deep rolling, superficial or deep boxcar, and icepick scars).<sup>11</sup> ECCA scores were calculated to compare treatment-associated changes.

Six months after final treatment, patients were asked to characterize their overall level of satisfaction as very satisfied, satisfied, slightly satisfied, or unsatisfied, with separate evaluations of each side of the face.

Patients were asked to report about the side effects of the treatment, especially post-therapy dyschromia, scaling or crusting, and erythema, also separately on each side of the face at each treatment session and follow-up visit. Immediately after each treatment, relative pain scores associated with the different modalities were evaluated using 10-cm visual analogue scales (VAS), with 0 being no pain and 10 being extremely painful.

For the histologic analysis, skin biopsies were performed using a 3-mm punch from the atrophic scars on each side of the face immediately after the first treatment. The biopsy specimens were fixed in 10% buffered formalin and embedded in paraffin. Each section was stained with hematoxylin and eosin.

### Statistical Analysis

Statistical analyses were performed using the Mann-Whitney test (for comparison between two lasers) and Wilcoxon signed rank test (for comparison of before and after laser treatments) using SPSS software (version 17.0, SPSS, Inc, Chicago, IL). Data were expressed as means plus or minus standard errors, and  $p < .05$  was considered statistically significant.

### Results

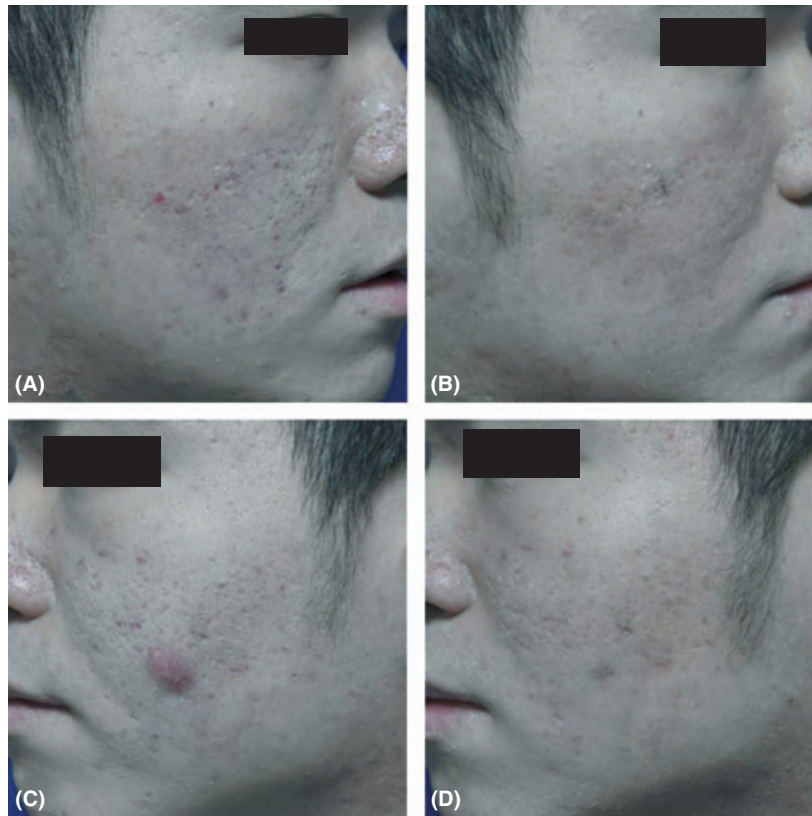
Thirty-three Chinese subjects with mild to severe atrophic acne scars, 14 female and 19 male, aged 19 to 34 (average  $26.4 \pm 3.7$ ) with Fitzpatrick skin types III and IV were enrolled in the study. The duration of scars

ranged from 1 to 10 years (average  $3.6 \pm 2.3$  years). All 33 subjects completed three treatments and a 6-month postprocedure follow-up visit.

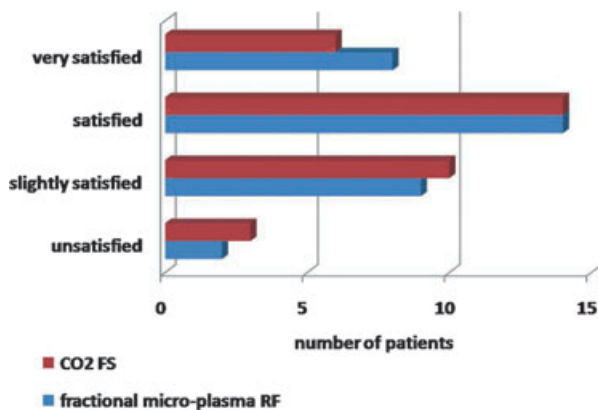
Overall, both modalities yielded a significant atrophic acne scar improvements 6 months after three treatments (Figure 1). ECCA scores fell significantly after fractional microplasma RF (from  $51.1 \pm 14.2$  to  $22.3 \pm 8.6$ , 56.4% improvement) and CO<sub>2</sub> FS (from  $48.8 \pm 15.1$  to  $19.9 \pm 7.9$ , 59.2% improvement) treatments (both  $p < .001$ ). The difference between the sides was not significant before ( $p = .53$ ) or after treatment ( $p = .93$ ). Improvement in ECCA scores were not significantly different between fractional microplasma RF and CO<sub>2</sub> FS (superficial rolling,  $p = .92$ ; deep rolling,  $p = .89$ ; superficial boxcar,  $p = .32$ ; deep boxcar,  $p = .51$ ; and icepick,  $p = .88$ ).

After fractional microplasma RF treatment, patient surveys regarding overall satisfaction revealed that 22 (66.7%) were very satisfied or satisfied, nine (27.3%) were slightly satisfied, and two (6.0%) were unsatisfied (Figure 2). After CO<sub>2</sub> FS treatment, 20 patients (60.6%) were very satisfied or satisfied, 10 (30.3%) were slightly satisfied, and three (9.1%) were unsatisfied. The overall satisfaction levels of fractional microplasma RF and CO<sub>2</sub> FS were not significantly different ( $p = .16$ ).

Side effects included pain during the treatment, post-treatment crusting or scaling, post-therapy erythema, and PIH (Table 1). The mean duration of post-therapy erythema and scaling was 5.7 days on the fractional microplasma RF sides and 10.2 days on the CO<sub>2</sub> FS sides ( $p < .001$ ). The mean erythema lasting days were noted 6.8 days on the fractional microplasma RF sides and 12.3 days on the CO<sub>2</sub> FS sides ( $p < .001$ ). Twelve subjects (36.4%) experienced postinflammatory hyperpigmentation (PIH) after 30 of 99 treatment sessions (30.3%) on the CO<sub>2</sub> FS side; no PIH was observed on the fractional microplasma RF sides ( $p < .001$ ). All cases of PIH were graded as mild except for one moderate case (Figure 3). The average duration of PIH was 45.8 days (range 14–90 days). All subjects with PIH



**Figure 1.** Atrophic acne scars of representative patients showed notable improvement at 6 months after three treatment sessions. (A and B) carbon dioxide fractional laser system treatment side versus (C and D) fractional microplasma radio-frequency treatment side (left column, baseline; right column, 6 months after three treatment sessions).



**Figure 2.** Patient satisfaction levels.

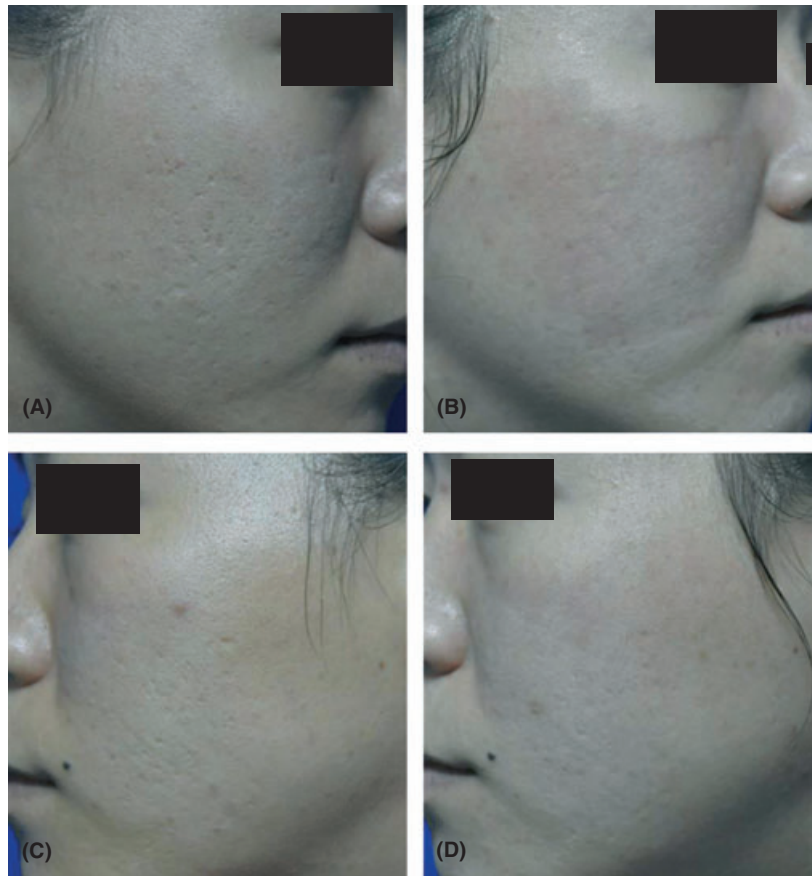
were successfully treated with 20% azelaic acid cream twice daily. Mean VAS pain scores were 5.9 with fractional microplasma RF treatments and 4.3 with CO<sub>2</sub> FS treatments ( $p = .003$ ).

**TABLE 1.** Adverse Events After Treatment with Fractional Microplasma Radio Frequency (RF) and a Carbon Dioxide Fractional Laser System (CO<sub>2</sub> FS)

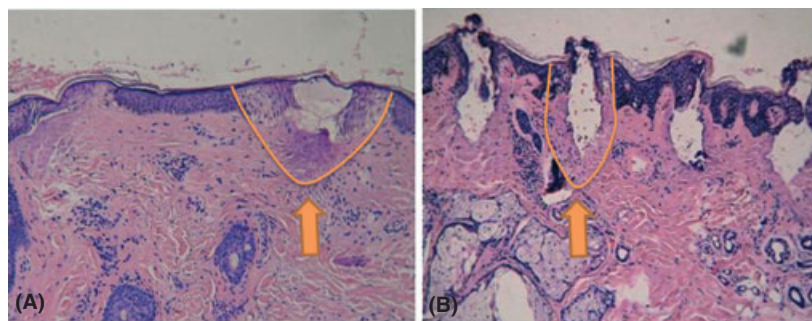
Side Effects	Fractional Microplasma RF	CO <sub>2</sub> FS
Crusting, scaling, mean ± SD*	5.7 ± 2.3	10.2 ± 3.1
Erythema, mean ± SD*	6.8 ± 3.8	12.3 ± 6.8
Postinflammatory hyperpigmentation, n (%) <sup>†</sup>	0 (0.0)	30 (30.3)
Pain, mean ± SD <sup>‡</sup>	5.9 ± 1.7	4.3 ± 1.5

SD, standard deviation.  
 \*Duration, days  
<sup>†</sup>No. of occurrences/ total treatment session (%)  
<sup>‡</sup>Visual analogue scales

Histopathologic experiments revealed that a fractional microplasma RF device generated cylindrical holes 120 to 150 μm deep, with diameter of 150 to



**Figure 3.** Atrophic acne scars of representative patients showed postinflammatory hyperpigmentation occurrence 2 months after one treatment. (A and B) carbon dioxide fractional laser system treatment side versus (C and D) fractional microplasma radio frequency treatment side (left column, baseline; right column, 2 months after one treatment).



**Figure 4.** Histologic evaluations of atrophic acne scars immediately after the first (A) fractional microplasma radio-frequency (RF) and (B) carbon dioxide fractional laser system (CO<sub>2</sub> FS) treatment (hematoxylin and eosin stain; original magnifications: ×400). Fractional microplasma RF resulted in a wider area of surrounding and subadjacent thermal damage than CO<sub>2</sub> FS did (arrow).

180 μm (Figure 4A). CO<sub>2</sub> FS produced bullet-shaped vaporization zones 300 to 400 μm deep, with a diameter of 100 to 120 μm (Figure 4B).

Fractional microplasma RF resulted in a wider area of surrounding and subadjacent thermal damage than CO<sub>2</sub> FS (arrow) (Figure 4).

## Discussion

Atrophic acne scars, one of the common complications of acne, can be physically challenging and psychologically devastating.<sup>12,13</sup> A number of options are available for the treatment of atrophic acne scars, including chemical peeling, dermabrasion, ablative and nonablative laser resurfacing, dermal fillers, and surgical techniques such as subcision and punch excision.<sup>14,15</sup> There are no methods of completely removing acne scars, so everything is a compromise. Ablative laser resurfacing using CO<sub>2</sub> or erbium-doped yttrium aluminum garnet lasers is the conventional treatment for acne scars, but laser treatment is associated with long recovery periods and possible serious adverse effects of infection, pigmentary changes, and scars.<sup>1,16,17</sup> An ablative 10,600-nm CO<sub>2</sub> fractional laser system has recently been introduced to maximize the effect of ablative laser therapies and minimize side effects by adopting fractional laser technology,<sup>18</sup> but for Fitzpatrick skin types III and IV in Asian populations, there is a risk of post-therapy hyperpigmentation.<sup>5</sup>

Fractional microplasma RF is a novel technology for skin resurfacing, skin remodeling, and the treatment of acne scars.<sup>8,9</sup> The Accent is a unipolar-based, RF-energy delivery device with fractional microplasma RF technology. With this technology, multiple RF plasma microdischarges are created in a gap between the applicator and the skin surface. When the applicator is a certain distance from the skin, the electromagnetic RF energy excites a grid of microsparks that cause mild epidermal ablation and perforate the dermis superficially. In addition, when the applicator contacts the skin, it creates unipolar RF effects. The combined ablative and thermal effects is effective for the treatment of atrophic acne scars.

To our knowledge, the present study provides the first clinical and histologic comparison of the efficacy and safety of fractional microplasma RF with that of CO<sub>2</sub> FS on atrophic acne scars in a

split-face manner. The results indicated that both modalities had good effects on treating atrophic scars at 6 months after three treatments. The improvement in ECCA scores and overall satisfaction between the fractional microplasma RF and CO<sub>2</sub> FS treatment sites were not significantly different. The most optimal parameter to characterize the effect of ablative fractional treatment is the percentage of ablated skin.<sup>19</sup> In this study, the coverage that the two modalities provided was similar (10% coverage with fractional microplasma RF, 10–20% coverage with CO<sub>2</sub> FS). The higher-energy (20–25 mJ), lower-coverage (10–20%) setting was selected for CO<sub>2</sub> FS treatments based on previous studies, especially those conducted in Asian population.<sup>6,20,21</sup> We agree that increasing coverage would result in better therapeutic effects, but it would also result in severe adverse effects such as PIH. PIH is a potential complication of CO<sub>2</sub> FS treatments in an Asian population. It was suggested that although energy and coverage parameters are both important considerations in reducing PIH in Asians, coverage is of particular importance. These studies concluded that high-energy, low-density treatment is more likely to prevent PIH.

The histopathologic results showed that CO<sub>2</sub> FS caused deeper ablation zones than the fractional microplasma RF device did, but fractional microplasma RF resulted in a wider area of surrounding and subadjacent thermal damage than CO<sub>2</sub> FS did. Hence, the therapeutic effects are correlated not only with the necrotic columns, but also with the surrounding thermal coagulated areas. Also, ECCA scores were not significantly different after fractional microplasma RF and CO<sub>2</sub> FS treatments according to scar type (superficial or deep rolling, superficial or deep boxcar, icepick).

Regarding complications, there was significantly more duration of crusting and erythema with CO<sub>2</sub> FS than fractional microplasma RF, which can enable earlier return to work and increase the patient's adherence to the treatment. Twelve

subjects (36.4%) experienced PIH after 30 of 99 treatment sessions (30.3%) on the CO<sub>2</sub> FS side, although PIH with the CO<sub>2</sub> FS treatment was mild and short lived. This result was in good correspondence with previously published data in Asian patients.<sup>5,7</sup> No PIH was observed after the fractional microplasma RF treatment. Several studies have demonstrated that PIH has not been observed in patients treated using fractional RF or fractional microplasma RF.<sup>8,22–25</sup> We hypothesized that the superficial subepidermal ablation generated by fractional microplasma RF therapy may reduce the inflammatory reaction, which facilitates re-epithelialization and results in lower incidence of PIH. Although there was more severe pain on the fractional microplasma RF sides than on CO<sub>2</sub> FS sides, it was not too severe (5.9/10) and lasted for just minutes.

In conclusion, we demonstrated the efficacy of the treatment of atrophic acne scars using fractional microplasma RF and CO<sub>2</sub> FS in Asian patients in a randomized, split-face, evaluator-blinded study. At the parameters selected for this study, PIH was not seen with the fractional microplasma RF, which is particularly important for patients with darker skin, so it is a good choice for treating atrophic acne scars in Asian patients. We believe that our study could be used as an essential reference when choosing laser modalities for scar treatment.

## References

- Alexiades-Armenakas MR, Dover JS, Arndt KA. The spectrum of laser skin resurfacing: nonablative, fractional, and ablative laser resurfacing. *J Am Acad Dermatol* 2008;58:719–37.
- Alser T, Zauyanov L. Laser scar revision: a review. *Dermatol Surg* 2007;33:131–40.
- Hantash BM, Bedi VP, Kapadia B, Rahman Z, et al. In vivo histological evaluation of a novel ablative fractional resurfacing device. *Lasers Surg Med* 2007;39:96–107.
- Lene H, Christina SH, Katrine TB, Morten KB, et al. Fractional CO<sub>2</sub> laser resurfacing for atrophic acne scars: a randomized controlled trial with blinded response evaluation. *Lasers Surg Med* 2012;44:447–52.
- Chan NP, Ho SG, Yeung CK, Shek SY, et al. Fractional ablative carbon dioxide laser resurfacing for skin rejuvenation and acne scars in Asians. *Lasers Surg Med* 2010;42:615–23.
- Cho SB, Lee SJ, Cho S, Oh SH, et al. Non-ablative 1550-nm erbium-glass and ablative 10 600-nm carbon dioxide fractional lasers for acne scars: a randomized split-face study with blinded response evaluation. *J Eur Acad Dermatol Venereol* 2010;24:921–5.
- Kim S, Cho KH. Clinical trial of dual treatment with an ablative fractional laser and a nonablative laser for the treatment of acne scars in Asian patients. *Dermatol Surg* 2009;35:1089–98.
- Halachmi S, Orenstein A, Meneghel T, Lapidoth M. A novel fractional micro-plasma radio-frequency technology for the treatment of facial scars and rhytids: a pilot study. *J Cosmet Laser Ther* 2010;12:208–12.
- Peterson JD, Palm MD, Kiripalsky MG, Guiha IC, et al. Evaluation of the Effect of Fractional Laser with Radiofrequency and Fractionated Radiofrequency on the Improvement of Acne Scars. *Dermatol Surg* 2011;37:1260–7.
- Dreno B, Khammari A, Orain N, Noray C, et al. ECCA grading scale: an original validated acne scar grading scale for clinical practice in dermatology. *Dermatology* 2007;214:46–51.
- Jacob CI, Dover JS, Kaminer MS. Acne scarring: a classification system and review of treatment options. *J Am Acad Dermatol* 2001;45:109–17.
- Layton AM. Optimal management of acne to prevent scarring and psychological sequelae. *Am J Clin Dermatol* 2001;2:135–41.
- Kellett SC, Gawkrödger DJ. The psychological and emotional impact of acne and the effect of treatment with isotretinoin. *Br J Dermatol* 1999;140:273–82.
- Goodman GJ. Treatment of acne scarring. *Int J Dermatol* 2011;50:1179–94.
- Walgrave SE, Ortiz AE, MacFalls HT, Elkeeb L, et al. Evaluation of a novel fractional resurfacing device for treatment of acne scarring. *Lasers Surg Med* 2009;4:122–7.
- Tierney EP, Eisen RF, Hanke CW. Fractionated CO<sub>2</sub> laser skin rejuvenation. *Dermatol Ther* 2011;24:41–53.
- Manuskiatti W, Triwongwanat D, Varothai S, Eimpunth S, et al. Efficacy and safety of a carbon-dioxide ablative fractional resurfacing device for treatment of atrophic acne scars in Asians. *J Am Acad Dermatol* 2010;63:274–83.
- Chapas AM, Brightman L, Sukal S, Hale E, et al. Successful treatment of acneiform scarring with CO<sub>2</sub> ablative fractional resurfacing. *Lasers Surg Med* 2008;40:381–6.
- Paasch U, Haedersdal M. Laser systems for ablative fractional resurfacing. *Expert Rev Med Devices* 2011;8:67–82.
- Cho SB, Lee SJ, Kang JM, Kim YK, et al. The efficacy and safety of 10600-nm carbon dioxide fractional laser for acne scars in Asian patients. *Dermatol Surg* 2009;35:1955–61.
- Jung JY, Lee JH, Ryu DJ, Lee SJ, et al. Lower-fluence, higher-density versus higher-fluence, lower-density treatment with a 10,600-nm carbon dioxide fractional laser system: a split-face, evaluator-blinded study. *Dermatol Surg* 2010;36:2022–9.
- Hruza G, Taub AF, Collier SL, Mulholland SR. Skin rejuvenation and wrinkle reduction using a fractional radiofrequency system. *J Drugs Dermatol* 2009;8:259–65.

23. Ramesh M, Gopal MG, Kumar S, Talwar A. Novel Technology in the Treatment of Acne Scars: the Matrix-tunable Radiofrequency Technology. *J Cutan Aesthet Surg* 2010;3:97-101.
24. Lee HS, Lee DH, Won CH, Chang HW, et al. Fractional rejuvenation using a novel bipolar radiofrequency system in Asian skin. *Dermatol Surg* 2011;37:1611-9.
25. Taub AF, Garretson CB. Treatment of Acne Scars of Skin Types II to V by Sublative Fractional Bipolar Radiofrequency and Bipolar

Radiofrequency Combined with Diode Laser. *J Clin Aesthet Dermatol* 2011;4:18-27.

---

Address correspondence and reprint requests to: Xiangdong Chen, MD, Department of Dermatology, Shanghai Ninth People's Hospital, Shanghai JiaoTong University School of Medicine, No. 639, Zhizaoju Road, Shanghai 200011, China, or e-mail: xdchen@medmail.com.cn