

Safe and Effective One-Session Fractional Skin Resurfacing Using a Carbon Dioxide Laser Device in Super-Pulse Mode: A Clinical and Histologic Study

Mario A. Trelles · Michael Shohat ·
Fernando Urdiales

Received: 30 March 2010 / Accepted: 25 July 2010

© Springer Science+Business Media, LLC and International Society of Aesthetic Plastic Surgery 2010

Abstract Carbon dioxide (CO₂) laser ablative fractional resurfacing produces skin damage, with removal of the epidermis and variable portions of the dermis as well as associated residual heating, resulting in new collagen formation and skin tightening. The nonresurfaced epidermis helps tissue to heal rapidly, with short-term postoperative erythema. The results for 40 patients (8 men and 32 women) after a single session of a fractional CO₂ resurfacing mode were studied. The treatments included resurfacing of the full face, periorcular upper lip, and residual acne scars. The patients had skin prototypes 2 to 4 and wrinkle degrees 1 to 3. The histologic effects, efficacy, and treatment safety in various clinical conditions and for different phototypes are discussed. The CO₂ laser for fractional treatment is used in super-pulse mode. The beam is split by a lens into several microbeams, and super-pulse repetition is limited by the pulse width. The laser needs a power adaptation to meet the set fluence per microbeam. Laser pulsing can operate repeatedly on the same spot or be moved randomly over the skin, using several passes to achieve a desired residual thermal effect. Low, medium, and high settings are preprogrammed in the device, and they indicate the strength of resurfacing. A single treatment was given with the patient under topical anesthesia. However, the anesthesia was injected on areas of scar

tissue. Medium settings (2 Hz, 30 W, 60 mJ) were used, and two passes were made for dark skins and degree 1 wrinkles. High settings (2 Hz, 60 W, 120 mJ) were used, and three passes were made for degree 3 wrinkles and scar tissue. Postoperatively, resurfaced areas were treated with an ointment of gentamycin, Retinol Palmitate, and DL-methionine (Novartis; Farmaceutics, S.A., Barcelona, Spain). Once epithelialization was achieved, antipigment and sun protection agents were recommended. Evaluations were performed 15 days and 2 months after treatment by both patients and clinicians. Treatment improved wrinkle aspect and scar condition, and no patient reported adverse effects or complications, irrespective of skin type, except for plaques of erythema in areas that received extra laser passes, which were not seen at the 2-month assessment. The results evaluated by clinicians were very much in correlation with those of patients. Immediately after treatment, vaporization was produced by stacked pulses, with clear ablation and collateral heat coagulation. An increased number of random pulses removed more epidermis, and with denser pulses per area, a thermal deposit was noted histologically. At 2 months, a thicker, multicellular epidermis and an evident increase in collagen were observed. Fractional CO₂ laser permits a variety of resurfacing settings that obtain safe, effective skin rejuvenation and correct scar tissue in a single treatment.

M. A. Trelles (✉)
Instituto Médico Vilafortuny, Fundación Antoni de Gimbernat,
Av. Vilafortuny, 31, E43850 Cambrils, Tarragona, Spain
e-mail: imv@laser-spain.com

M. Shohat
Ichilov Hospital, Tel Aviv, Israel

F. Urdiales
Instituto Médico Miramar, Malaga, Spain

Keywords Ablative resurfacing · CO₂ laser ·
Fractional resurfacing · Single fractional treatment ·
Skin rejuvenation

Skin resurfacing is a prevalent and acceptable means of inducing an improvement in the skin's appearance. Carbon dioxide (CO₂) laser resurfacing produces controlled skin

damage, with removal of the epidermis and variable portions of the dermis [1]. Associated dermal heating results in collagen shrinkage and collagen remodeling [2]. The dermal tightening achieved and the associated new epithelium gives a youthful appearance to the skin, with improved texture and reduced lines and wrinkles. The most common indications for resurfacing are photoaging, including skin elastosis, rhytides, lentigines, and scar revision, particularly those associated with residual acne scarring.

As many new technologies are developed to turn back the signs of aged skin, ablative resurfacing with CO₂ laser still remains the gold standard for erasing and smoothing out rhytides, photodamaged skin, and acne scars [3]. However, unparalleled in its efficacy, CO₂ laser resurfacing has a high risk–benefit ratio [4, 5].

Fractional ablative laser therapy is a new method of skin resurfacing, which when practiced with the CO₂ laser, offers an interesting alternative to the typical conventional procedure of eliminating the full layer of skin. The remaining epidermis that has not been resurfaced helps tissue to repair more rapidly, which translates into a speedy recovery time and a shorter postoperative period of erythema. The efficacy of the CO₂ laser thermal effect is kept within a limited side-effect profile [6].

During ablative fractional resurfacing treatment, tiny microscopic pieces of skin are vaporized, and a thermal deposit occurs in the dermis. At the time of repair, tissue is restored with active fiber formation, which produces a tightening effect, and the external aspect of the skin is improved [7, 8]. The degree of improvement in the results of fractional CO₂ laser resurfacing is related to the density of superficial microtissue elimination and the thermal deposit left in the dermis, which, to a large extent, is related to laser power, pulse width, and the density of microzones of tissue elimination, determined by the number of passes over the treated area.

We present the results obtained for 40 patients (8 men and 32 women) and the associated symptoms observed after a single session of CO₂ ablative fractional resurfacing using the so-called “pixel mode,” in which technology splits the laser beam into several microbeams. We also examine the histologic effects, the efficacy, and the safety of the treatment in various clinical conditions, including aged photodamaged facial skin and acne-scarred skin of patients with different phototypes.

Materials and Methods

The Laser Device

The laser used was the Pixel CO₂ Laser System (Alma Lasers Ltd., Caesarea, Israel). This system operates in

continuous mode at a power of 1 to 60 W and offers super-pulse mode selection, specifically used for fractional resurfacing. The output power, on-time exposure, off time, and pulse-repetition rate are managed by a microprocessor, which controls the operational treatment method of the laser settings. The handpiece incorporates novel fractional laser beam technology attached to the articulated delivery arm. The handpiece can be fractional, with 7 × 7 or 9 × 9 pixels, or surgical, with a 50- and 100-mm focal length.

The operator can select power levels (high, medium, or low) and individual beam energy expressed in millijoules of either 9 × 9 (81 pixels) or 7 × 7 (49 pixels). The energy for the two beams (9 × 9 or 7 × 7) range between 10 and 500 mJ/pixel. Thus, the operator can choose less or more thermal damage by changing the tips (9 × 9 or 7 × 7) and by changing the power (high, medium, or low). When the laser is programmed for fractional resurfacing, it can be operated in super-pulse (repeat) mode between 0.5 and 5 Hz.

For clinical application, laser settings require a power adaptation to meet a required fluence per microbeam for different tissue responses (less or more thermal damage) within a preset on-time exposure according to three fixed energy super-pulse options offered by the manufacturer: low (20 W), medium (30 W), or high (60 W). Low, medium, and high levels of energy for treatment correspond to a different number of laser on-time exposures or pulses per second (PPS). The number of PPSs is displayed on the device console screen together with the energy in millijoules applied by each beam spot of the grid.

The “high” program selection demands an increase in laser power, which at the tissue level produces rapid vaporization, leaving a deposit of residual heat in the dermis. The “low” program selection, however, produces a greater dermal heat effect and less vaporization.

The preset operating parameters for fractional resurfacing are based on various clinical conditions displayed with their corresponding initials on the LCD touch-control screen. The initials are SR for skin resurfacing, AC for acne, WR for wrinkles, and FL for fine lines. The possibility also exists of selecting the operation mode (OP), which allows the operator to open the control and set the parameters freely for fractional treatment.

At the time of ablative fractional resurfacing, the microlesions formed depend, to a large extent, on the spacing of the beams. The density of microholes per area leaves more or less unaffected bridges of skin, which are significant in the speed of tissue reepithelialization and also affect the risk of adverse events. The penetration of the tiny laser beams in the dermis is based on the laser power according to the high-, medium-, or low-energy program. More evident residual thermal damage will be related to the number of super pulses within the on-time exposure that lead to

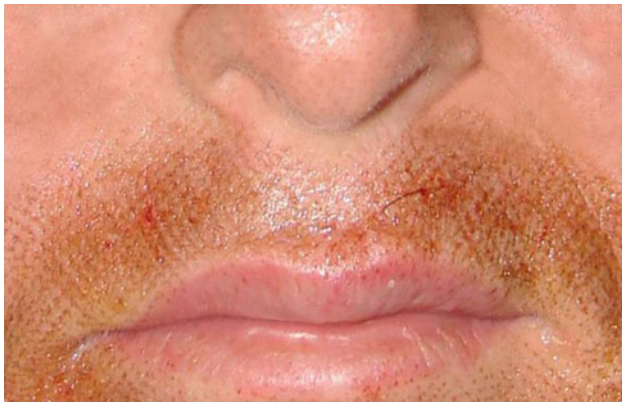

Fig. 1 Brownish color caused by random passes in this case of perioral fractional carbon dioxide resurfacing

greater tissue inflammation, with a direct implication of collagen formation at the time of tissue repair.

When the settings are programmed for fractional resurfacing, the laser can work by pulsing energy in stacked mode, that is to say, the handpiece is positioned stationary on the same treatment point, and various pulses are delivered. At this moment, tissue removal occurs deeper, and heat buildup is transmitting to neighboring tissue. If the handpiece is moved randomly over the skin, several laser passes are carried out on the skin surface, which produce a higher density of microholes. When this occurs, the treated area turns a brownish color, with tinier pieces of superficial skin removed, and depending on the number of passes, a residual thermal effect in tissue also is achieved (Fig. 1).

Patients and Treatment

The results for the 40 patients (8 men and 32 women) treated in this study are presented. The patients ranged in age from 22 to 58 years (mean age, 48 years). All the patients underwent only one treatment using the pixel grid of 7×7 (49 microbeams). The pixel diameter was 150 μm , and the pixel area was 0.000176625. The laser was programmed in super-pulse mode (60 W, high), and the pulse duration was 0.1 s. Therefore, the joules per pixel were $60 \times 0.1/49 = 0.1224489$ J/pixel, and the fluences per pixel were 693 J/cm².

Of the 40 patients, 24 underwent full-face resurfacing, 10 had upper-lip resurfacing, and 6 had periocular resurfacing. Of the 24 patients who underwent full-face resurfacing, 10 had residual acne scars. The 40 patients represented 8 skin phototype 2 cases, 20 phototype 3 cases, and 12 phototype 4 cases.

The study group included 20 patients with degree 3 wrinkles, 8 with degree 2 wrinkles, and 12 with degree 1 wrinkles (Tables 1 and 2). The degree 1 wrinkles were fine and visible, with facial movement related to mild elastosis,

Table 1 Patient demographics

Ages (years)	Skin phototype			Wrinkle degree		
	2	3	4	1	2	3
22–35	2	6	2	1	0	0
36–47	3	6	7	11	7	4
48–58	3	8	3	0	1	16

some textural changes, and a few skin lines in the area of mimics. The degree 2 wrinkles were defined as a moderate number of fine wrinkles at rest in addition to moderate-to-deep wrinkles in motion associated with moderate elastosis and some dyschromia. The degree 3 wrinkles were a large number of fine to moderately deep wrinkles at rest and very deep wrinkles with movement related to severe elastosis, thickened yellow multipapular skin, and dyschromic lesions.

No patient was pregnant or nursing or had any inflammatory skin disease or active acne condition. Treatment and expected postoperative skin condition was explained in detail to each patient, and all signed an informed consent for surgery, histologies, and the use of clinical photography. The inclusion of patients for the study and the use of corresponding data were approved by the Ethics Committee of the Antoni de Gimbernat Foundation.

Table 3 shows the CO₂ laser program chosen and the treatment technique with the number of passes carried out. The patients were visited 2 and 7 days after resurfacing for follow-up assessment, and the results obtained were evaluated 15 days and 2 months after treatment. Evaluation was based on examination and comparison of skin condition before and after resurfacing. Also, efficacy of treatment was evaluated by the patient and the physicians rating their satisfaction with the outcome obtained.

For treatment, topical anesthesia was used (EMLA MAX; Laboratorios Astra España, S.A., Barcelona, Spain). Anesthesia was applied 3 h before treatment with an occlusive dressing. The skin then was gently washed and conscientiously dried. Next, a local anesthetic, mepivacaine 2% without vasoconstrictor (Scandinibsa, Laboratorios Inibsa, S.A., Lliça de Vall, Barcelona, Spain), was injected in the areas that showed scar tissue. Also, each patient was given 10 mg of diazepam and 1 g of paracetamol orally 20 min before surgery. Patients were prepared with an intravenous catheter in case they required extra analgesia or sedation.

Fractional resurfacing then was initiated at the same time that a cold air flow, programmed at #5 fan speed, was constantly focused on the treated area (Cryo 5, Zimmer Electromedicine, Ulm, Germany). The nozzle of the air device was kept close to the skin to help mitigate the pain and reduce the burning sensation experienced during treatment.

Table 2 Area treated and clinical indications

Skin phototype	Clinical indication			Treatment area		
	Acne scars (<i>n</i>)	Wrinkles & skin tightening (<i>n</i>)	Skin rejuvenation (<i>n</i>)	Full face (<i>n</i>)	Upper lip (<i>n</i>)	Periocular (<i>n</i>)
2	0	0	8	6	0	2
3	8	7	5	12	4	4
4	2	9	1	6	6	0

Table 3 Laser settings used

Skin condition treated	Power and fluence per pixel W/mJ	Program	No. of passes	Treatment technique
Wrinkles & skin tightening	60/120	WR/high	2 + 3 extra passes on areas of more important wrinkles	Stacking mode followed by laser handpiece rotation
Skin resurfacing & rejuvenation	30/60	Medium	2	Two passes to obtain high density of microbeam pulses
Acne scars	60/120	WR/high	4–6 passes on scar tissue + 2 on whole face	Rotation of handpiece on scar or borders + 2 passes on the whole face

WR wrinkles

Within the preset offer, the “high” program was chosen with the WR operation mode and two to three passes for degree 3 wrinkles and skin tightening irrespective of skin phototype. On the other hand, the “medium” super-pulse program with the laser emitting in WR at 30 W and 60 mJ per microbeam was used for dark skin phototypes and degree 1 wrinkles. Two laser passes were performed to produce a higher density of microbeams per area. Irrespective of the program chosen for treatment, the repetition rate of one pulse per second was maintained.

In all cases, three extra passes were carried out for areas of skin with more important wrinkles or signs of skin aging and laxity. In the areas with deeper wrinkles, the handpiece was maintained fixed for the stacking mode for the first two laser passes, then rotated for the other two or three extra passes to increase heat deposit in tissue.

In the case of residual acne scars, the treatment program selected was high, at 60 W and 120 mJ per microbeam, the same as for degree 3 wrinkles and skin tightening. In these cases, the whole face was treated, but resurfacing started with the scarred tissue, which received four to six passes, with the handpiece rotated to increase the number of microbeam pulses per area. The laser beam was aimed particularly at the edge of the scars if they were depressed, or focused on the scars themselves if they were elevated. Then, the whole face received full treatment with two passes, which also were given over the scar area. For this, the handpiece was rotated to achieve a homogeneous distribution of laser beam microholes per unit of area treated. Then, an additional two random passes also were applied on those areas that presented small skin imperfections due

to acne scarring to obtain more heat deposition and to increase the tissue coagulation effect.

Once treatment was completed, the same postoperative treatments were given to all patients. An ointment based on gentamicin, Retinol Palmitate, and DL-methionine applied four times a day in small amounts over the whole treated area by gentle massaging was recommended. In the case of full-face and upper-lip resurfacing, application of acyclovir (Zovirax cream, GlaxoSmithKline Ltd., Madrid, Spain) on the lip vermillion as a moisturizer three times per day for 5 days was recommended.

No oral antiherpes medication was recommended based on our previous controlled studies [9]. Washing of the treated area with a mild cleanser was permitted only on the fourth day after resurfacing. Then, daily washing was carried out gently so as not to force scab detachment. From day 5 onward, ointment was ceased, and a reparative cream based on calendula (TT₁ reparative postresurfacing cream; Laboratory Profarplan, Barcelona, Spain) was indicated [10]. At the 7-day follow-up assessment, an antipigment cream based on 2% kojic acid, 2% alpha hydroxy acid, and 4% hydroquinone (TT₂ antipigment cream; Laboratory Profarplan) was prescribed for day 10 as a night ointment until the 2-month control assessment if the areas treated were scab free, [11]. The patients were recommended to avoid direct exposure to the sun.

Although the patients were instructed to return for follow-up visits at 2 and 7 days, evaluation of results was only at 15 days and 2 months after treatment. However, the patients received instructions to report any possible adverse effects and to have daily telephone contact with the nurses,

all experts in assisting the resurfacing procedure. The patients were to communicate any particular occurrence and make sure that the postoperative evolution was going according to the instructions received.

Photographs of all the patients were taken before treatment, then 15 days and 2 months after treatment using a Sony digital camera (Sony CyberShot, 5.1 mega pixels; Sony, Tokyo, Japan) at a fixed distance, respecting light and ambient conditions. Photographs also were taken during treatment to identify the pattern produced on the skin with the various modes of microbeams for fractional resurfacing. As a representative cross sample of the study, 10 patients were randomly selected for biopsies before and immediately after resurfacing and at the 2-month assessment. Tissue samples were routinely processed and stained with haematoxylin–eosin (H&E) for identification of tissue evolution.

At the 15-day and 2-month control assessments, all the patients were interviewed by two different clinicians, both experts in laser resurfacing who were not involved in the treatment. Scoring of the outcome also was explained to all the patients: worse (W) when treatment had made the skin condition worse than before treatment, fair (F) when only 25% success had been achieved, good (G) when 50% success was achieved, and very good (VG) when a 75% improvement was obtained. The same scoring was used by the clinicians when examining patients before and then 15 days and 2 months after the photographs.

No 100% results were expected due to skin characteristics and the fact that only a single treatment session was carried out. In fact, because some patients presented degree 3 wrinkles or acne scar tissue, it was predictable that one session of fractional ablative resurfacing could not totally (100%) remove all lesions. Moreover, our personal experience with conventional and fractional resurfacing [12, 13] and the results obtained with various sessions of ablative fractional treatment for several other patients not included in this study showed that no 100% results can be expected with one fractional resurfacing treatment session.

Results

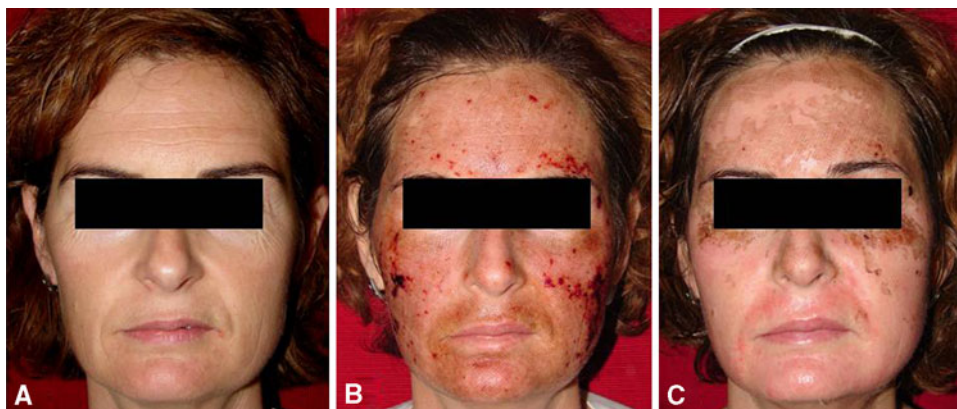Although ablative CO₂ laser fractional resurfacing was performed at a fixed repetition rate of 1 Hz, the patients treated with the “high” program that included more super pulses within on-time exposure obtained evident ablative effects with tissue removal including an improved wrinkle aspect, a better scar tissue condition, an enhanced skin aspect, and a younger appearance. The skin after treatment was smoother for all the patients. However, areas that had more wrinkles before resurfacing and received extra laser passes showed more evident erythema (Figs. 2 and 3).

When the stacking mode was used and followed by random passes of the handpiece, patients reported greater discomfort, a burning sensation, and pain. Despite the application of cold air and topical anesthesia, the patients found the treatment of these areas painful. This was not the case when areas with acne scars were treated because the injection of local anesthetic prevented discomfort, and treatment was conducted without any problems. None of the 40 treated patients refused to complete the treatment.

Patients treated with the “medium” program using fewer super pulses per on-time laser exposure still experienced some discomfort, but the pain was bearable. This program setting was found to be effective for treating fine lines and degree 1 wrinkles, and the skin reepithelialized rapidly. The relatively long pulse interval and fewer super pulses permitted by this program produced less tissue ablation, enabling refreshment of the skin aspect and removal of solar pigmentation with good control of collateral heat deposition.

Immediately after surgery, the patients reported a burning sensation, and the skin was a brownish color, particularly in the areas that had received extra laser passes. Depending on the repeated pulses given by each laser pass, microholes produced by the fractional resurfacing in the stacking mode produced deeper laser penetration in the dermis and more evident collateral residual thermal damage, which was seen in the histologies (Fig. 4).

Fig. 2 Various stages of before and after fractional resurfacing. **a** Before: Evident signs of skin laxness and wrinkles. Aspect **b** 2 days after and **c** 7 days after, with scabs almost gone



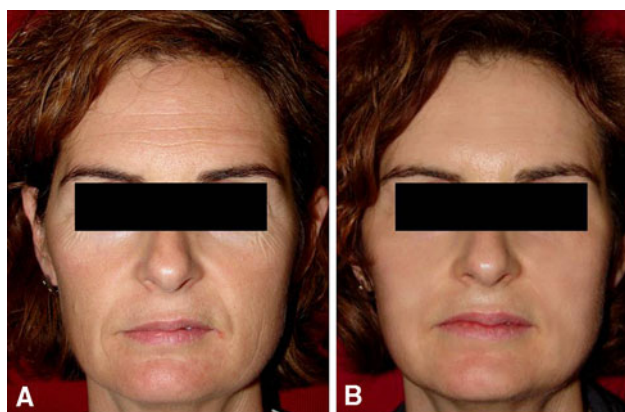

Fig. 3 Same patient as Fig. 2 a before and b 2 months after. Notice the evident improvement

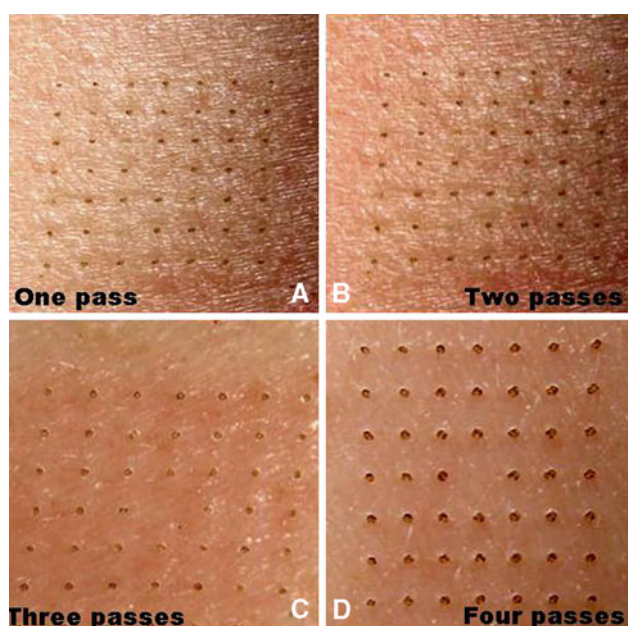


Fig. 4 Visual appearance of the so-called stacking mode for fractional resurfacing. Various passes have been performed without moving the handpiece. a, d Clear increase in superficial damage, which in the dermis translates into greater thermal deposition

Scabs produced with the “medium” program took 4 to 5 days to fall off compared with those produced by the WR high program used for degree 3 wrinkles and areas of scar tissue, with the scabs requiring a further 4 days to disappear. No patient reported complications of any sort except for plaques of erythema, which were apparent in the areas that received extra treatment. In any case, the patients had been advised before treatment to expect such a reaction. No changes in pigmentation were noted at the 2 month assessment, but changes in pigmentation were difficult to assess at the 15-day control assessment except in one phototype 4 patient treated for acne scars. Erythema at this

time was present and more visible in accordance with extra treatment given in areas of deeper wrinkles or scar tissue.

These variations in skin color, tone, and redness could not be clearly evaluated as being pigmentation. Nevertheless, some degree of skin darkness was noted in three patients with phototype 4 skin at the 15-day assessment, which had disappeared by the 2-month control visit. At the 15-day control assessment, no patient was erythema free, but this was easily camouflaged with colored makeup, and by no means was skin redness as intense as that which occurs with the use of conventional CO₂ resurfacing [14].

By the 2-month control visit, no changes in pigmentation were seen in any patient, irrespective of their skin types. No scarring, herpes infections, or any other adverse effect was observed. Because collection of data for this paper terminated more than 6 months previously, we had the opportunity to follow all the patients up to the time of this writing, reaffirming our statement that no complications had arisen.

At the 15-day evaluation, the new epithelialized skin was fine and fresh looking. Fine lines had disappeared, and the patients were told that a more notable effect on higher-degree wrinkles would be noticed after a few weeks due to the tightening effects of expected new collagen formation. All the patients were erythema free 2 months after treatment, and the skin tightening effect was clearly noticeable (Fig. 5).

The best and most homogeneous younger skin appearance was achieved when the whole face was resurfaced. In fact, when facial skin was partially treated, improvements in the treated areas markedly contrasted with the untreated areas. As for the treatment of acne scars, patients were satisfied, and all noticed more evident improvement at the 2-month assessment (Fig. 6). Typically, improvement achieved with the treatment of scar tissue tends to get better with time, but 2 months after treatment, a potential increase in benefits expected and evaluation of improvement are possible [12].

Table 4 presents results achieved and correlates scores given by patients and clinicians according to clinical indication and area of treatment at the 15-day and 2-month evaluations. As seen in Table 4, improvement “in the eyes” of the patients and clinicians was more evident at 2 months. Scores given by the clinicians after examining photographs before treatment and consulting with patients at 15 days and 2 months correlated very closely with the patients’ evaluations, especially those at 2 months. There were no “worse” results according to the opinion of the patients.

Histologic control of laser effects immediately after fractional laser resurfacing in the stacking and random modes showed the depth of tissue vaporization produced by one and two stacked pulses. It is clear that each super-pulse

Fig. 5 **a** View before full-face fractional resurfacing phototype 2, degree 3 wrinkles. **b** View 15 days after, with the skin in better condition, free of scabs. **c** View 2 months after evaluation, with further improvement in the outcome showing skin tightening

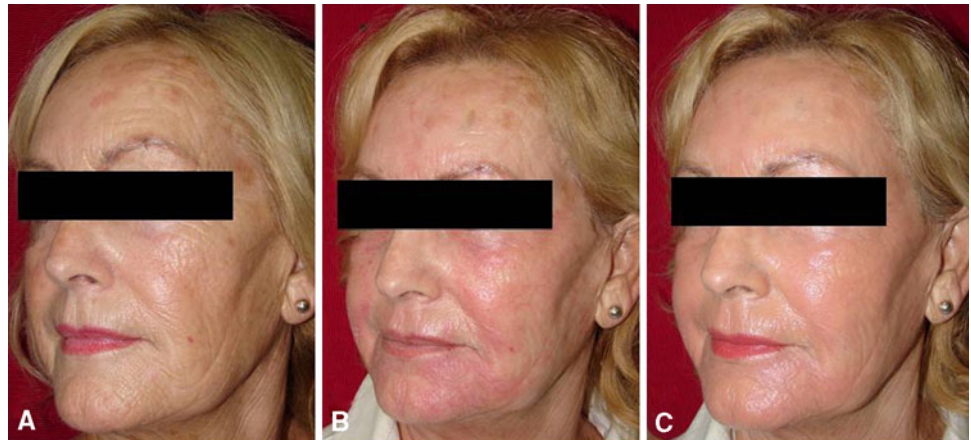
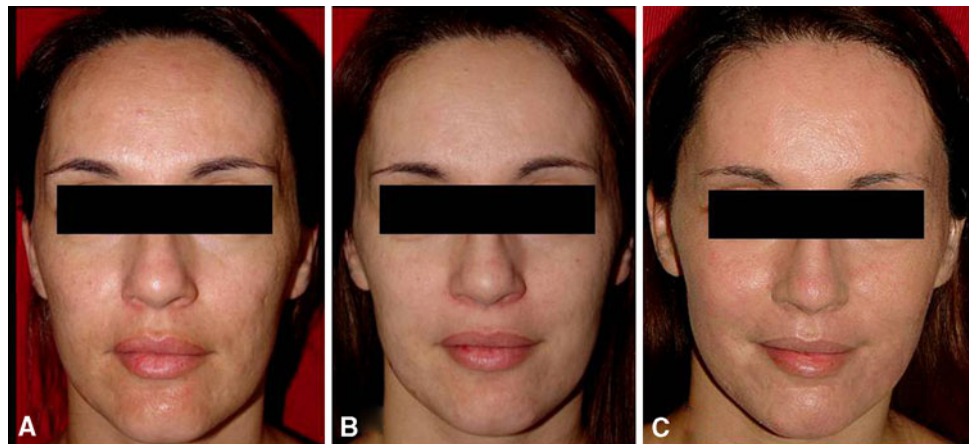
Fig. 6 Residual acne scars, treated together with a full-face procedure. Notice the progressive improvement over time **a** before, **b** 15 days after, and **c** 2 months after fractional resurfacing



microbeam pulse enters deeper into the dermis with clear ablation and increased collateral residual heat effect and tissue coagulation (Fig. 7).

The macrophotography and histology of the random mode of fractional resurfacing in which the handpiece moves in rotation, packing a higher number of micropulses onto the skin surface, are clearly noticed visually and represented microscopically by more extended, more homogeneous epidermis removal with a mild thermal deposition. When random pulses are applied with the “high” program, more epithelium is removed, leaving fewer untreated skin bridges. Again, with closer pulses, thermal deposition is noticed, which extends beneath the skin surface at the time that a more extensive band of epidermis is vaporized in correlation with the number of laser passes applied (Figs. 8 and 9).

Residual heat signs in the dermis were more obvious when more micropulses were packed per pulse, that is, when the density of laser pulses and the deposition of laser energy were higher. This was in accordance with a larger pulse width and more super pulses packed per on-time of the CO₂ laser. For cases treated with the “high” program, 2-months after treatment, the dermis displayed better and more noticeable new, dense collagen fibers (Fig. 10). The fibers

ran parallel immediately below and attached to the epidermal–dermal junction. Also, compared with lax expression of dermal fibers, they appeared more compact 2 months after resurfacing, with narrower interfibrillary spaces. There was some inflammation and vascular neoformation.

The 2-month histologies compared with those taken before CO₂ laser fractional resurfacing presented a wavier, thicker, multicellular epidermis and a well-structured, fine, keratin layer. In the dermis, fibers appeared denser than before treatment. In general, the aspect of tissue samples was more in accordance with younger skin, different from before treatment, when the tissue was dull with disordered fibers and evident signs of elastosis, especially that of patients with more severe wrinkles. Two examples of photographs before and 2 months after clinical treatment show the results of treatment of two different skin conditions (Figs. 11 and 12).

Discussion

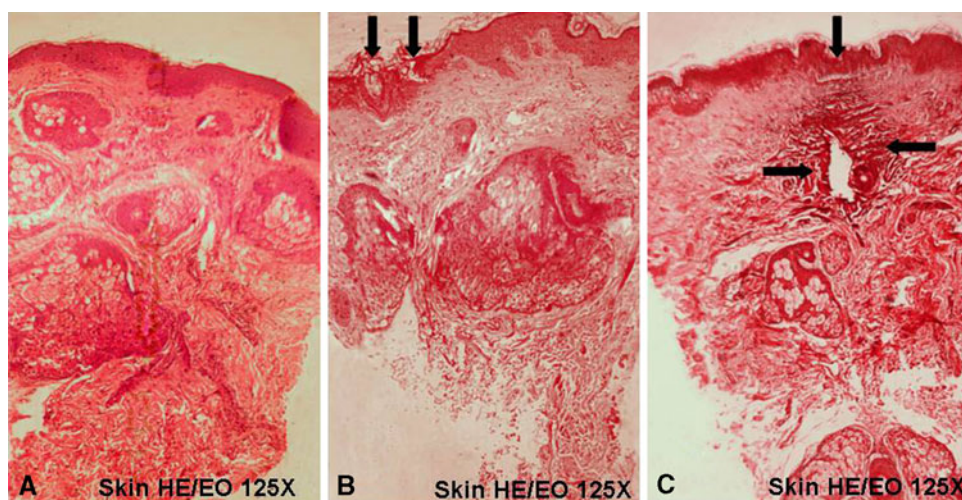
Fractional laser beam resurfacing improves wrinkle appearance and serves to renew external and internal signs of skin elastosis and photoaging, as previously reported

Table 4 Results at 15 days and 2 months

No.	Clinical indication	Area of treatment	Assessment				No.	Clinical indication	Area of treatment	Assessment			
			15 days		2 months					15 days		2 months	
			Patient	Clinician	Patient	Clinician				Patient	Clinician	Patient	Clinician
1	Wr 3	Full face	G	VG	G	VG	21	Wr 3	Periocular	F	G	F	G
2	Wr 3	Full face	G	G	G	VG	22	Wr 3	Upper lip	F	G	G	G
3	Wr 1 (AS)	Full face	G	G	G	G	23	Wr 2	Periocular	F	G	G	G
4	Wr 3	Full face	F	G	G	G	24	Wr 1 (AS)	Full face	G	G	VG	VG
5	Wr 2	Upper lip	F	G	VG	VG	25	Wr 1 (AS)	Full face	F	G	G	VG
6	Wr 3	Upper lip	G	G	G	G	26	Wr 3	Periocular	F	F	F	G
7	Wr 3	Periocular	F	G	F	G	27	Wr 1 (AS)	Full face	G	G	G	G
8	Wr 3	Full face	F	G	G	VG	28	Wr 2	Periocular	G	G	G	G
9	Wr 3	Full face	G	G	G	G	29	Wr 3	Full face	F	G	VG	VG
10	Wr 2	Upper lip	F	G	G	G	30	Wr 2	Full face	G	G	F	G
11	Wr 3	Full face	G	G	VG	VG	31	Wr 1 (AS)	Full face	G	F	F	G
12	Wr 3	Full face	F	G	G	G	32	Wr 3	Full face	F	F	G	G
13	Wr 1	Upper lip	F	G	VG	VG	33	Wr 3	Full face	F	G	G	G
14	Wr 1 (AS)	Full face	G	G	VG	VG	34	Wr 3	Full face	G	G	G	G
15	Wr 3	Full face	F	G	G	VG	35	Wr 3	Upper lip	F	F	G	G
16	Wr 1 (AS)	Full face	G	G	G	VG	36	Wr 2	Upper lip	F	G	G	VG
17	Wr 2	Periocular	F	G	G	G	37	Wr 3	Full face	G	G	G	G
18	Wr 1 (AS)	Full face	F	G	G	G	38	Wr 1 (AS)	Full face	F	G	G	G
19	Wr 2	Upper lip	F	G	F	G	39	Wr 3	Upper lip	F	G	G	G
20	Wr 1 (AS)	Full face	F	G	G	G	40	Wr 3	Upper lip	F	G	G	G

Wr wrinkles (degrees 1, 2, & 3), AS acne scarring, W worse, F fair, G good, VG very good

Fig. 7 a Histologies representing skin condition hematoxylin-eosin (HE/EO) $\times 125$ before treatment. **b** One stacked pulse showing full penetration of the whole epidermis (arrows). **c** An extra pass, stacking on the same point, fully enters the dermis, giving rise to lateral residual thermal tissue coagulation (arrows indicate coagulated dermis)



[15–18]. Ablative CO₂ laser with the optical fractional beam mode permits a variety of resurfacing treatment-adapting settings and number of passes as well as the operation of the handpiece on the same area to obtain, in just one session, a clear improvement in the condition and signs of aging skin. The aim of giving a single treatment is to meet patient

compliance as well as possible and to avoid repetition of scabbing at every session and the posttreatment stage, which is accompanied by sick leave and absence from work. A single treatment session respects safety, obtains a high level of efficacy, and still permits a rapid reepithelialization and recovery of good skin condition.

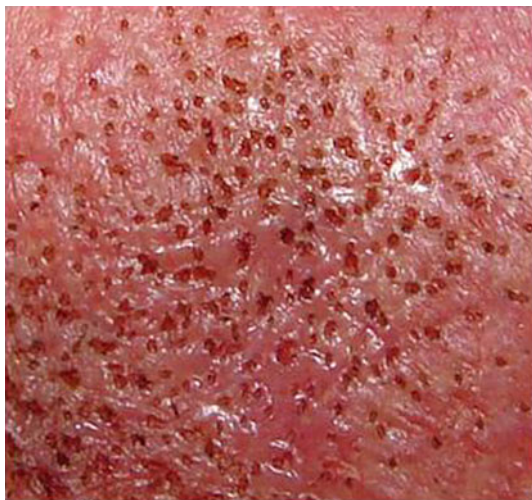

Fig. 8 Macroscopic visual aspect of various random pixel passes over the skin. With a higher density of pulses per area, a more evident tissue removal occurs. Three passes were performed

A single treatment session aims to gain the greatest effect possible, and this is based, to a large extent, on the monitoring of tissue thermal reaction. The amount of

heat deposited in the dermis after fractional epidermis removal, together with columns of dermal tissue, develops an active reparative reaction typical of wound repair, with the formation of new fibers characteristic of young skin.

Although the treatment for acne scars and deeper wrinkles was more robust in the current series, scabs were resolved within a maximum of 8 to 12 days, and it was possible to use makeup from day 7. The patients preferred to undergo only one treatment so as not to be absent several times from their normal activities [19]. For the patients presenting with acne scars, degree 3 wrinkles, or skin laxity in certain areas of the face needing more active treatment, the extra laser passes and the higher action of thermal damage eventually led to a more active collagen formation effect [20, 21]. A sequence of repeated random laser pulses produces a buildup of residual heat. Moreover, when energy packs more super pulses per laser on-time, thus keeping the delivery between the super pulse operations short, thermal effects are extended to adjacent tissue. As a consequence, coagulation takes place, and the clinical results show tissue tightening and improvement of sagging

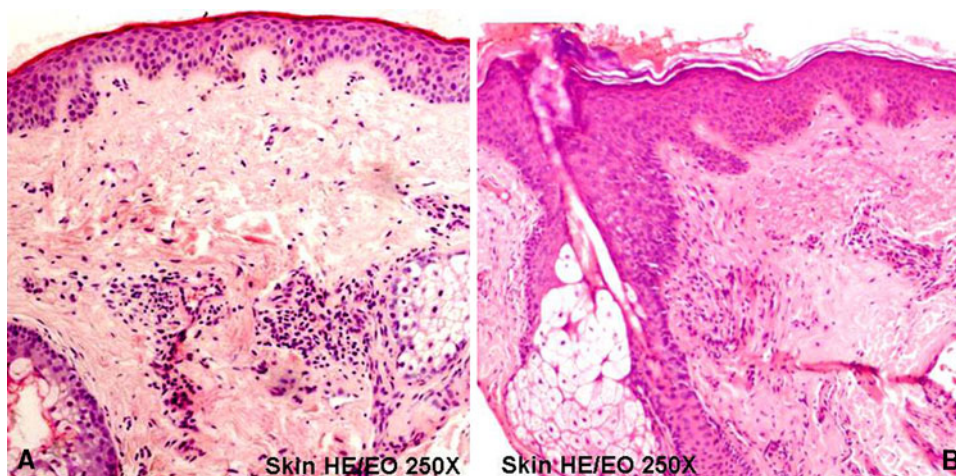
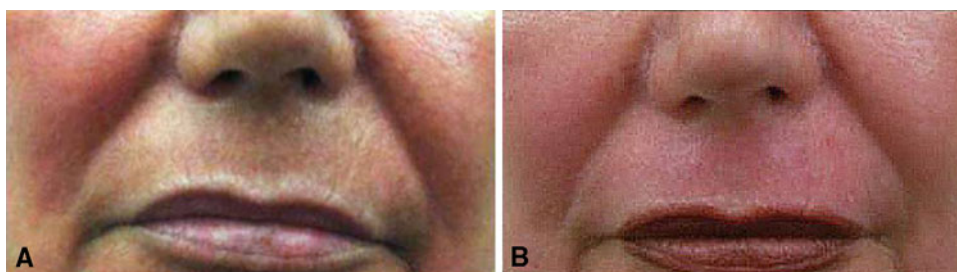


Fig. 9 **a** Skin hematoxylin-eosin (HE/EO) $\times 250$ before fractional resurfacing showing epidermis structure with a few cell layers. Slight pigmentation is seen at the basal layer without significant alterations. The dermis shows evident signs of elastosis with random disposition of fibers and wide interfibrillary spaces. Some isolated erythrocytes of the vessels can be noted. **b** Skin HE/EO $\times 250$ 2 months afterward.

Histologies corresponding with degree 3 wrinkles present a better condition of the tissue, with improved fiber alignment running parallel to the epidermal–dermal junction, representing a new, more compact collagen. Less noticeable interfibrillary spaces are observed in the dermis. The epidermis is thicker than before, wavy, and multicellular, more in correspondence with a younger skin condition

Fig. 10 Before and 15 days after fractional pixel treatment of the upper lip. **a** Wrinkles are evident, and skin aging is present. **b** View 2 weeks after. Wrinkles have practically disappeared, but some residual erythema is visible



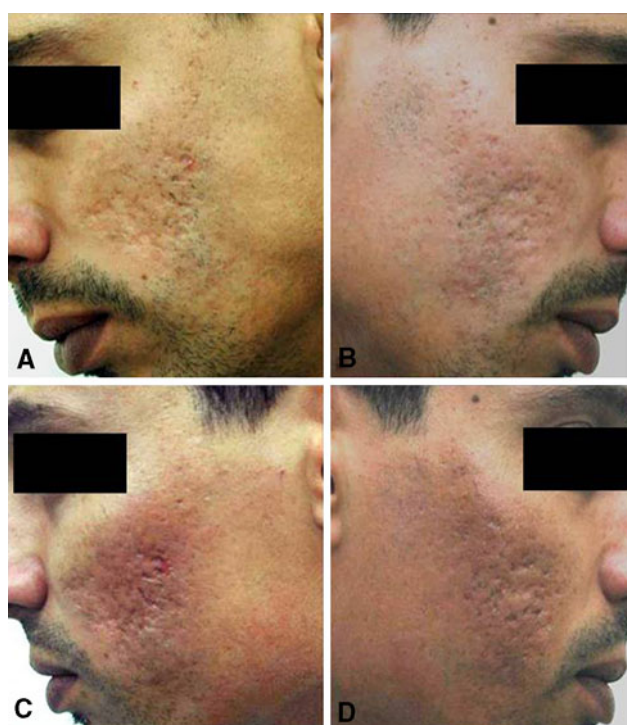


Fig. 11 Patient phototype 5 **a, b** before and **c, d** after 2 months of pixel fractional resurfacing of residual scars. Improvement is clearly noticeable

skin. This effect was more noticeable for degree 3 wrinkles with extended elastosis and lax skin.

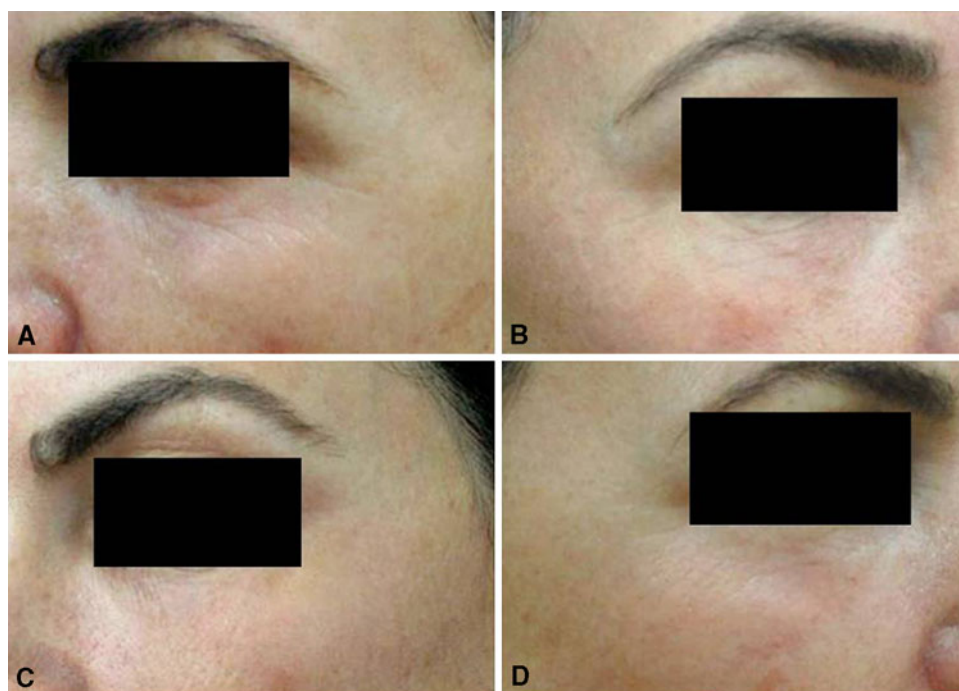
Treatment for fine lines, a low wrinkle degree, and some tissue elastosis using two passes with the medium setting,

which has a relatively large off-operation super-pulse laser interval, produces a clear ablation effect but with little coagulation effect due to more constrained thermal deposition. In the case of scar tissue, treatment initiated by stacking laser pulses without moving the handpiece followed by its rotation to obtain a higher density of pulses per area of skin on the edges of the depressed scars achieves both epidermis elimination and good thermal deposition to boost collagen production and tighten the skin. Typically, resurfaced tissue tends to improve with time, enhancing the skin aspect rather than worsening it, clinically and histologically [22, 23].

Interestingly, irrespective of the treatment program used and the density of the microholes produced on the skin, with large amounts of epidermis removed, reepithelialization is rapidly achieved, requiring from 8 to a maximum of 12 days for scabs to fall off. The effective and rapid repair of the treated areas is one advantage of the device used in this study for fractional ablative resurfacing, with relatively rapid resolution of erythema and no hyperpigmentation, as observed in our study.

We consider that the apparent erythema that patients could present at the 2-month control assessment are the signs of new, refreshed resurfaced skin. The optical absorption of the skin typically changes its index after laser resurfacing and, as a consequence, shows a clearer pinkish color [14]. Moreover, the use of antipigment agents, such as those used for all the patients and described in the report, tends to preserve a little redness of the skin (easy to camouflage with some colored makeup). But, this redness

Fig. 12 a, b Before and **c, d** 2 months after periorcular fractional pixel carbon dioxide laser resurfacing. Skin condition is improved, with clear tightening



was not defined as actual erythema, and the patients accepted this when they were interviewed.

The same applies for the “hyperpigmentation.” Both the patients and the expert clinicians considered the redness or the apparent hyperpigmentation to be within the normal limits of tissue condition after resurfacing. The patients were aware of these signs before undergoing treatment because they were informed beforehand what to expect.

Compared with the erbium:yttrium-aluminium-garnet (Er:YAG) laser, CO₂ laser resurfacing demands a longer period for the wound to repair, but tissue tightening and fibroplasia per micrometer depth of damaged skin is more evident and lasts longer [1, 2]. This effect in tissue is clinically reflected by the achievement of longer-lasting results with the CO₂ laser fractional treatment than with the fractional Er:YAG laser, although the equivalent depth of the dermal wound is produced during resurfacing [24, 25].

Laser skin rejuvenation treatment requires time for the final improvement to be seen because new collagen fibers need a few weeks to be well and produce the tightening action. This supports the fact that improvement seen at 2 months is better than the scores given at the 15-day evaluation after resurfacing, and it is expected that it will continue to improve in the following months [13].

Hyperpigmentation as a complication was not seen at the 2-month assessment. In fact, it was noticed only at the 15-day assessment in one dark phototype case managed for acne scars, but it was solved by the time of the 2-month evaluation. This, again, is one advantage of fractional resurfacing in contrast to the results presented by Scarborough et al. [3] and Tan et al. [26].

Nevertheless, a cream maintenance program should be indicated for all patients after treatment. We consider that this helps skin to recover faster and to prevent hyperpigmentation, as seen in our 40 treated patients [27].

Acknowledgments The report presented in this study is registered in the academic activities of the FUNDACION ANTONI DE GIMBERNAT year 2009–2010.

References

1. Ross E, McKinlay J, Anderson R (1999) Why does carbon dioxide laser resurfacing work. *Arch Dermatol* 135:444–445
2. Trelles MA, Rigau J, Pardo L, Garcia-Solana L (1999) Electron microscopy comparison of CO₂ laser flash scanning and pulse technology one year after skin resurfacing. *Int J Dermatol* 38:58–64
3. Scarborough D, Saap L, Bisaccia E (2006) Exploring aesthetic interventions: the gold standard in facial resurfacing: the CO₂ laser and future directions, vol 14. HMP Communications, LLC. <http://www.skinandaging.com/article/6271>. Accessed 25 March 2010

4. Trelles MA, Levi JL, Pardo L, Kontoes V, Soria C (2000) Complication du relissage laser CO₂: Une revue de 728 patients. *J Med Esthet Chir Dermatol* 27:169–174
5. Berlin AL, Hussain M, Phelps R, Goldberg DJ (2009) A prospective study of fractional scanned nonsequential carbon dioxide laser resurfacing: a clinical and histopathologic evaluation. *Dermatol Surg* 35:222–228
6. Fife DJ, Fitzpatrick RE, Zachary CB (2009) Complications of fractional CO₂ laser resurfacing: four cases. *Lasers Surg Med* 41:179–184
7. Groff WF, Fitzpatrick RE, Uebelhoefer NS (2008) Fractional carbon dioxide laser and plasmakinetic skin resurfacing. *Semin Cutan Med Surg* 27:239–251
8. Gold MH (2007) Fractional technology: a review and clinical approaches. *J Drugs Dermatol* 6:849–852
9. Trelles MA, Rigau J (1997) Proceso de Curación de las Heridas. Cuidados Postoperatorios. ¿Pueden Evitarse las Complicaciones en el Resurfacing Láser? *Dermocosmet Clin* 5:20–27
10. Trelles MA, Garcia-Solana L, Allones I (2003) Ensayo clínico y de Laboratorio de una crema de caléndula en el post resurfacing láser (Clinical laboratory trials of a calendula cream following laser resurfacing). *Cir Plást Ibero-Latinoamericana* 29:11–24
11. Garcia-Solana L, Allones I, Vélez M, Trelles MA (2002) Función de los cosméticos en el resurfacing láser. *Int J Cosmetic Med Surg* 4:151–154
12. Trelles MA (2004) Laser ablative resurfacing for photorejuvenation based on more than a decade’s experience and 1, 200 patients: Personal observations. *J Cosmet Dermatol* 2:2–13
13. Trelles MA, Mordon S, Vélez M, Urdiales F, Levy JL (2009) Results of fractional ablative facial skin resurfacing with the erbium-yttrium-aluminium:yttrium-aluminum-garnet laser 1 week and 2 months after one single treatment in 30 patients. *Lasers Med Sci* 24:186–194
14. Trelles MA, Mordon S, Svaasand LO, Mellor TK, Rigau J, Garcia L (1998) The origin and role of erythema after carbon dioxide laser resurfacing: a clinical and histological study. *Dermatol Surg* 24:25–29
15. Manstein D, Herron GS, Sink RK et al (2004) Fractional photothermolysis: a new concept for cutaneous remodelling using microscopic patterns of thermal injury. *Lasers Surg Med* 34: 426–438
16. Kono T, Chan HH, Groff WF, Manstein D, Sakurai H, Tekeuchi M, Yamaki T, Soejima K, Nozaki M (2007) Prospective direct comparison study of fractional resurfacing using different fluences and densities for skin rejuvenation in Asians. *Lasers Surg Med* 39:311–314
17. Tannous Z (2007) Fractional resurfacing. *Clin Dermatol* 25: 480–486
18. Geronemus RG (2006) Fractional photothermolysis: current and future applications. *Lasers Surg Med* 38:169–176
19. Trelles MA, Pardo L, Ayliffe P, Trelles K, Vélez M, Garcia Solana L (2001) Patients’ answers to a postoperative questionnaire related to laser resurfacing. *Facial Plast Surg* 17: 187–192
20. Hasegawa T, Matsukura T, Mizuno Y, Suga Y, Ogawa H, Ikeda S (2006) Clinical trial of a laser device called fractional photothermolysis system for acne scars. *J Dermatol* 33:623–627
21. Lee HS, Lee JH, Ahn GY, Lee DH, Shin JW, Kim Dh, Chung JH (2008) Fractional photothermolysis for the treatment of acne scars: a report of 27 Korean patients. *J Dermatol Treat* 19:45–49
22. Trelles MA, Rigau J, Pardo L, Garcia-Solana L (1999) Electron microscopy comparison of CO₂ laser flash scanning and pulse technology one year after skin resurfacing. *Int J Dermatol* 38:58–64
23. Trelles MA, Garcia-Solana L, Rigau J, Allones I, Vélez M (2003) Pulsed and scanned carbon dioxide laser resurfacing 2 years after

- treatment: comparison by means of scanning electron microscopy. *Plast Reconstr Surg* 111:2069–2078
24. Trelles MA, Vélez M, Mordon S (2008) Correlation of histological findings of single session Er:YAG skin fractional resurfacing with various passes and energies and the possible clinical implications. *Lasers Surg Med* 40:171–177
 25. Kauvar A (2000) Laser skin resurfacing: Perspectives at the millenium. *Dermatol Surg* 26:174–177
 26. Tan KL, Kurniawati C, Gold MH (2008) Low risk of postinflammatory hyperpigmentation in skin types 4 and 5 after treatment with fractional CO₂ laser device. *J Drugs Dermatol* 7:774–777
 27. Trelles MA, Trelles K, Allones I, Romero C, Vélez M (2008) Cuidados post resurfacing: Láser en dermatología y dermocosmética. *Aula Médica*, Chapt. 9.4, pp 387–392. ISBN:978-847885-445-5